



Short- and long term follow-up of 150 sports horses diagnosed with tendinopathy or desmopathy by ultrasonographic examination and treated with high-power laser therapy

M. Pluim^{a,b}, A. Martens^c, K. Vanderperren^d, S. Sarrazin^e, M. Koene^b, A. Luciani^b, P.R. van Weeren^f, C. Delesalle^a

^a Department of Virology, Parasitology & Immunology, Research Group Comparative Physiology, Faculty of Veterinary Medicine, Ghent University, Salisburylaan 133, 9820 Merelbeke, Belgium

^b Tierklinik Luesche, Essenerstrasse 39a, 49456 Bakum, Germany

^c Department of Surgery and Anaesthesiology of domestic animals, Faculty of Veterinary Medicine, Ghent University, Salisburylaan 133, 9820 Merelbeke, Belgium

^d Department of Veterinary Medical Imaging and Small Animal Orthopedics, Faculty of Veterinary Medicine, Ghent University, Salisburylaan 133, 9820 Merelbeke, Belgium

^e Department of obstetrics, Reproduction and herd health, Faculty of Veterinary Medicine, Ghent University, Salisburylaan 133, 9820 Merelbeke, Belgium

^f Department of Equine Sciences, Utrecht University, Yalelaan 1, 3584, CL, Utrecht, the Netherlands

1 Introduction

Tendon and ligament injuries are common in sport horses. They are among the primary reasons for not returning to the previous performance level and are therefore often career ending (Dyson et al., 1995; Dyson, 2004; Gillis, 2016). Even if successful, due to the low turn-over of tendon tissue, healing is challenging. Inflammatory-, repair- and remodeling- phases of tendon healing are complex and time consuming, entailing a substantial career-break in virtually all cases (Dyson, 2004; Gillis, 2016; Kaneps, 2016). A wide plethora of treatment approaches have been tried over time, including but not restricted to local or systemic application of anti-inflammatory drugs, intratendinous injections with corticosteroids, -aminopropionitrilefumarate (Dyson, 2004), polysulfated glycosaminoglycans, platelet-rich-plasma (Wasselau et al., 2008; Bosch et al., 2010; Castelijns et al., 2011; Geburek et al., 2016), autologous conditioned serum (Arquelles et al., 2008) or stem cells (Smith, 2008; Godwin et al., 2012), counter irritation, surgery (tendon splitting, proximal check ligament desmotomy) and shockwave therapy (Crowe et al., 2004). Overall, results have been variable at best, explaining the continuous quest for new avenues to treat tendinopathy in horses.

Low-power laser therapy (power output < 500 mW) has been used in both human and veterinary medicine for decades. Both *in vitro* and *in vivo* studies report biologic effects of this type of treatment, such as increased fibroblast proliferation and collagen production (Guerra Fda et al., 2013), improvement of collagen-fiber alignment (Carrinho et al., 2006), increase in tendon tensile strength (Elwakil, 2007; Demir et al., 2013; Marcos et al., 2014; Casalechi et al., 2013), increased collateral circulation and angiogenesis (Larkin et al., 2012; Maegawa et al.,

2000), decreased levels of pro-inflammatory mediators, such as PGE-2, TNF- α , IL-1 and IL-6 (Marcos et al., 2012; Laraia et al., 2012; Bjordal et al., 2006; Pires et al., 2011). Reports on clinical effects are ambiguous (Pryor, 2011; Wiegerinck et al., 2012; Morimoto et al., 2013; Lam and Cheing, 2007; Stergioulas et al., 2008; Bingol et al., 2005; Basford et al., 2008), which may be related to the fact that the depth of penetration of low-power laser devices is deemed to be insufficient to treat deeper tissues (Ryan and Smith, 2007). For this reason, in human medicine various pathologies such as tendinopathies (Mardh and Lund, 2016), whiplash injuries (Conforti and Fachinetti, 2013), back- and neck pain and other orthopedic sports injuries (Larkin et al., 2012) are treated with high-power laser (output > 500 mW). In the last few years the offer of high-power laser devices on the veterinary market has increased, but thus far no reports on possible efficacy have been published.

The aim of the current exploratory retrospective clinical study was to obtain data about the possible clinical value of high-power laser therapy by evaluating short and long-term outcome in a group of 150 sports horses, diagnosed with tendinopathy or desmopathy. Based on our clinical impression on previous experiences it was hypothesized that high-power laser therapy could be applied safely and that outcome would be at least comparable to outcomes for other treatment modalities reported in literature.

2 Material and methods

2.1. Study design

Retrospective observational clinical study involving 150 sport

Corresponding author at: Department of Virology, Parasitology & Immunology, Research Group Comparative Physiology, Faculty of Veterinary Medicine, Ghent University, Salisburylaan 133, 9820 Merelbeke, Belgium.

E-mail address: mpluim@tierklinik-luesche.de (M. Pluim).

<https://doi.org/10.1016/j.rvsc.2018.06.003>

Received 25 March 2018; Received in revised form 24 May 2018; Accepted 10 June 2018

horses that were admitted to Equine Hospital, Tierklinik Lüsche, Germany, and were diagnosed with either superficial (SDFT) or deep digital exor (DDFT) tendinopathy or desmitis of the suspensory ligament (SL) or its branches (SLB), on either front- or hind limb, and that were treated with high-power laser therapy.¹ Diagnosis was based on a complete clinical lameness exam, followed by ultrasonographic assessment palmar/plantar, lateral and medial of the metacarpus/metatarsus (Esaote Mylab5, linear probe, 10MHz²). Lameness and ultrasonographic scoring were repeated twice after the initial admission exam: the day after cessation of laser therapy (week 2) and 4 weeks later (week 6). Long-term information was obtained by means of a telephone inquiry at 6, 12 and 24 months after first admission. The following parameters were recorded: age, gender, sports discipline, level of performance, lameness score, type of tendinopathy or desmopathy (SDFT, DDFT, SL or SLB), ultrasonographic score (stage (acute, subacute or chronic) and severity of the lesion (Supplementary Table 1)), lesion at day 0 being recurrence of an earlier lesion or not, presence of more than one orthopedic problem, additional therapy during the designed period of the study or not, time to return to controlled exercise, time to return to previous performance level and occurrence of re-injury (recurrence in the same area) after treatment or not. Level of previous performance varied between patients (ranging from non-competing to high level competition horses), therefore “return to competition” is not a suitable parameter in this study population.

2.2. High-power laser therapy

The high-power laser device (Fig. 1) used is a diode laser with a maximum output-power of 15,000 mW. It emits laser light with four different wavelengths simultaneously: 635 nm, 660 nm, 810 nm and 980 nm and is equipped with sensors that register local temperature and micro-impedance at the irradiated area. The output of the device is controlled by a feedback loop regulated by an internal encrypted algorithm that is based on a mathematical model which produces approximations of the diffusion of laser light through different biological tissues and that takes into account the sensor output (Conforti and Fachinetti, 2013) (Fig. 2). The approximate amount of power delivered per treated cm³ tissue was 250 J.

Treatment was started 2 days after the horse was diagnosed in the clinic with tendinopathy or desmopathy (either acute, subacute or chronic) and included in the current study. In case additional therapy was instituted, laser therapy was initiated 2 days after additional therapies were applied (such as intra- or perilesional injection, shock-wave or surgical intervention). All horses were treated during 2 consecutive weeks once a day during 20 min by a trained technician with a protocol pre-set for the specific anatomic structure by the manufacturer of the laser device (Touch Life rehab). Horses have not been sedated and treatment was applied over a clipped (blade size 0.5 mm) area over the full length of the lesion. The skin was scrubbed and degreased with alcohol and the laser hand piece was held perpendicular to the skin surface at a distance of 0.5 cm after which movements were made fast in a linear pattern upon the lesion area.

Laser therapy was applied either alone or, at the discretion of the treating veterinarian, in combination with an additional therapy such as: intra- or perilesional injections of autologous conditioned plasma (ACP), platelet-rich plasma (PRP), fat-derived stem cells, bionic cells, hyaluronic acid, tiludronic acid, shockwave therapy or surgical interventions (tenovaginoscopy, desmotomy of the check ligament, splint bone removal or fasciotomy) (Fig. 3).



Fig 1 FP4 System .

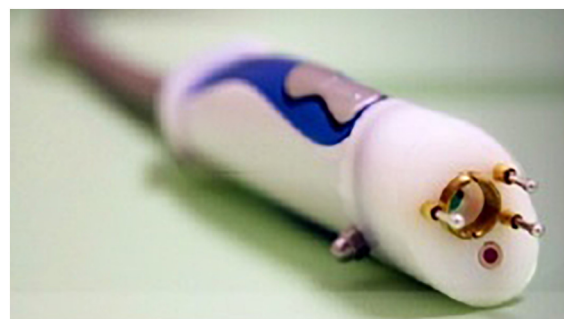

Fig 2 Hand piece of FP4 System .

2.3. Lameness score, type, stage and severity of tendinopathy or desmopathy

Lameness was scored on an adapted AAEP scale (0–5): grade 0 (no lameness), grade 1 (slight lameness in trot only), grade 2 (moderately lame in trot only), grade 3 (slightly lame in walk and severely lame in trot), grade 4 (moderately lame in walk, severely lame in trot), and grade 5 (severely lame in walk or non-weight bearing) (Stashak, 2002). Lameness was scored independently by 2 veterinarians (the veterinarian responsible for the case and a varying orthopedic colleague) on each occasion (admission, week 2 and week 6). In case of differences in appraisal, the higher lameness score was retained for statistical purposes.

Lesion stage was classified as either: acute (< 3 weeks), subacute (3–6 weeks) or chronic (> 6 weeks) based on case history. Lesions were further categorized by clinical appearance (heat, pain, swelling). Ultrasonographic assessment was performed (MP) using a pre-designed clip recording protocol (Supplementary Table 1) to enable blinded scoring by a second veterinarian (AL). Transverse and longitudinal clips were recorded from the palmar/plantar, medial and lateral side of the injured structure on a standing and flexed limb and scored on a semi-quantitative scale (modified from Ramzan et al. (2013)) to classify the severity of the lesions (none, mild, moderate or severe). Supplementary table 1 presents detailed data on the specific ultrasonographic features that were appraised. Ultrasonographic scoring was performed independently by 2 veterinarians (the veterinarian performing the ultrasonographic examination and a second blinded veterinarian scoring the recordings) on each occasion. In case of differences, the worst score was retained for statistical purposes.

¹ Manufacturers' address: FP4 System, Touch Life Rehab, Bergamo, Italy.

² Manufacturers' address: MyLab Five, Esaote Benelux, Maastricht, The Netherlands.

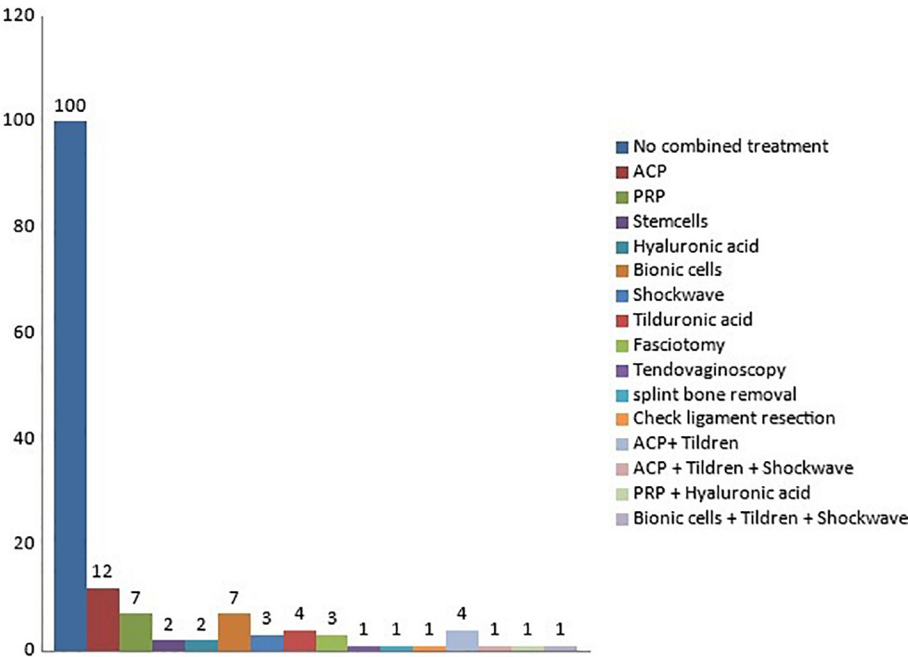


Fig 3 Additional treatments.

2.4. Rehabilitation and follow-up

All horses were at the beginning of the protocol subjected to a similar rehabilitation protocol (Fig. 4). However, monthly clinical and ultrasound checks were used to guide adjustments to the protocol, as in this population of high-level sport horses in a clinical setting an effort was made to rehabilitate the horses as fast as possible.

Long-term information was gathered by telephone inquiry asking for: (1) the actual performance level at that time point (not performing, performing at a lower level than before, performing at the same or higher level than before); (2) the possible reason if the previous performance level had not been reached yet (initial injury, another orthopedic problem or other); (3) time to return to controlled exercise (trotting exercise under the saddle); (4) time to return to previous performance level.

2.5. Statistical analysis

A first pair of outcome variables were the ordinal variables ‘ultrasonographic score’ and ‘lameness score’ at day 0 and weeks 2 and 6. For each outcome variable a longitudinal cumulative logit model was built using the ‘multgee’ package in the R software (<http://cran.r-project.org>) to take into account the correlation between outcomes of the same horse at different occasions. A category exchangeability structure was assumed to model the within-subject correlation. A model with only the time of examination (day 0, week 2 or 6) was fitted to assess the effect of time on the outcomes. Odds ratios (ORs) were estimated with their corresponding 95% confidence intervals (95% CI) for the GEE models, where an OR above 1 for class of a predictor variable denotes that horses in that class had a better ultrasonographic or lameness score compared to horses in the reference class of that predictor variable. The

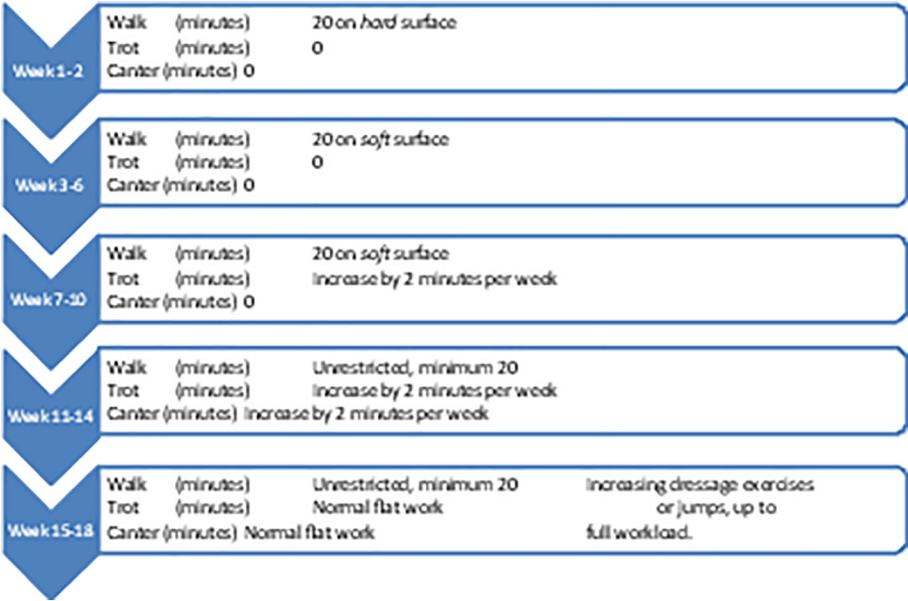


Fig 4 Rehabilitation protocol.

proportional odds assumption was tested using the 'repolr' package.

A second pair of outcome variables of interest were 'time to return to controlled exercise' and 'time to return to previous performance level'. Both outcomes were explored using a Kaplan-Meier estimator and the log-log transformation for calculation of 95% confidence intervals in the 'proc lifetest' procedure in SAS 9.4 (SAS Institute Inc., Cary, NC, USA). A multivariable Cox regression model was built using the 'phreg' procedure. Hazard ratios (HRs) with their corresponding 95% CI were estimated for the survival models, where a HR above 1 for class of a predictor variable denotes that horses in that class returned sooner to controlled exercise or previous performance level compared to horses in the reference class of that predictor variable. Residuals were explored to verify the overall model fit and proportional hazard assumption.

The predictor variables that were considered for association with the outcome variables were: (1) the type of tendinopathy or desmopathy (SDFT, DDFT, SL, SLB), (2) the stage of the disorder, (3) the disorder at day 0 being recurrence or not, (4) use of additional therapy and (5) existence of multiple causes for lameness. For each model first a univariable analysis was performed. Subsequently, predictor variables with a p -value < 0.20 were combined in a multivariable model. Significance was set at 5%. Odds ratios for the GEE models and hazard ratios for the survival models were estimated with their corresponding 95% CI.

Re-injury rates and rehabilitation times were compared with those described in literature.

3 Results

3.1. Study population characteristics

Sport horses ($n = 150$), aged between 3 and 21 years (mean \pm standard deviation (SD); 9.6 ± 2.1 years) and mainly active in either jumping ($n = 60$ horses; 40%) or dressage ($n = 72$; 48%). The remaining horses were pleasure horses ($n = 9$; 6%) or active in eventing ($n = 4$; 2.7%) and other disciplines (driving, western sports, Icelandic racing; $n = 5$; 3.3%). The majority ($n = 95$; 64%) competed at a high (international) level, 37 (25%) at a medium level and 26 (17%) at a low level (lower than German "L" level). The following tendinopathies or desmopathies were diagnosed: SDFT ($n = 30$; 20%), DDFT ($n = 12$; 8%), SL ($n = 67$; 45%) and SLB ($n = 41$; 27%). There were 64 (43%) acute, 37 (25%) subacute and 49 (33%) chronic cases. In twenty-eight (19%) horses the tendinopathy or desmopathy was recurrent (but had not been treated before with laser). In 65 (43%) cases, another orthopedic pathology, e.g. osteoarthritis, was present as well at the time of treatment. In 50 (33%) horses, laser treatment was combined with other treatment modalities (Fig. 3).

3.2. Short-term follow-up

Laser therapy was successfully and uneventfully applied in all horses. Data were complete for all horses. There was a significant amelioration in lameness and ultrasonographic scores after high-power laser treatment over time (Figs. 5 and 6). At week 2 the estimated OR of having a better ultrasonographic score below any fixed level k , i.e. a better score, compared to "score at admission" was 3.0 (95% CI 2.4; 3.9; $P < 0.001$), while at week 6 the corresponding estimated OR increased to 7.5 (95% CI 5.2; 10.9; $P < 0.001$). Similarly, the estimated OR of having a better lameness score at week 2 compared to "score at admission" was 5.1 (95% CI 3.7; 7.1; $P < 0.001$), while at week 6 the corresponding estimated OR increased to 11.1 (95% CI 7.1; 17.4; $P < 0.001$). None of the predictor variables were significantly associated with the ultrasonographic score following univariable and multivariable analysis: type of tendinopathy ($P = 0.1$), stage ($P = 0.3$), recurrent injury ($P = 0.1$), combination therapy ($P = 0.3$) and multiple orthopedic problems ($P = 0.4$).

Considering the lameness score, the predictor variable "stage" was not retained following univariable analysis ($P = 0.7$), while type of tendinopathy or desmopathy ($P < 0.01$), recurrent injury ($P = 0.09$), combination therapy ($P = 0.05$) and multiple orthopedic problems ($P = 0.1$) were considered for multivariable analysis.

In the final multivariable model significant differences between types of tendinopathy or desmopathy ($P < 0.01$) were noticed. At admission, horses with either a DDFT (OR = 0.46; 95% CI 0.13; 1.6; $P = 0.2$), a SLB (OR = 0.25; 95% CI 0.10; 0.66; $P < 0.01$) or SL (OR = 0.17; 95% CI 0.07; 0.41; $P < 0.001$) lesion were more likely to have a worse lameness score compared to horses with an SDFT lesion. This difference in lameness score between tendinopathies was not significant at later time points (week 2 and 6).

Horses receiving a combination therapy were more likely to have a worse lameness score at week 6 compared to horses receiving only laser therapy (OR = 0.35; 95% CI 0.14; 0.88; $P = 0.03$). This difference was not significant at admission, nor at week 2. The proportional odds assumption was not violated ($P = 0.60$). Use of an additional therapy was significant ($P < 0.01$) at week 6 with horses receiving an additional therapy having worse outcome.

3.3. Long-term follow-up

Data were successfully collected after 6, 12 and 24 months in respectively 129 (87%), 119 (80%) and 33 (22%) horses. Re-injury rates (at previous lesion location) were respectively 16.8%, 21.0% and 18.2% (Table 1). Long-term follow up data were not available for all horses due to owner change (and privacy issues), lack of actual contact details of the owner, or death of the horse. For 124 out of 129 horses the exact time to controlled exercise was known. Based on data of these 124 horses the median time interval to return to controlled exercise was 6 weeks. The predictor variables "additional therapy" and "lesion stage" were retained in the multivariable model, while no significant associations were found between outcome and either 'type of tendinopathy or desmopathy' ($P = 0.4$), 'multiple causes of lameness' ($P = 0.4$) and 'recurrent injury at day 0' ($P = 0.2$). Horses that received an additional therapy were likely to need more time to initiate controlled exercise compared to horses that received only laser therapy (HR = 0.66; 95% CI 0.44; 0.99; $P = 0.05$). Horses with a sub-acute (HR = 1.2; 95% CI 0.7; 1.9; $P = 0.5$) or chronic injury (HR = 1.6; 95% CI 1.0; 2.5; $P = 0.04$) were more likely to start controlled exercise earlier compared to horses with an acute injury.

Based on data of 129 horses the median time interval to return to the previous performance level was 6 months (95% CI 5; 7). Following univariable and multivariable analysis only the variable "recurrent injury at day 0" was significantly associated with the outcome ($P = 0.03$), while no significant associations were found with the type of tendinopathy or desmopathy ($P = 0.2$), lesion stage ($P = 0.3$), presence of multiple causes of lameness ($P = 0.6$) and additional therapy ($P = 0.1$). Horses with a recurrent injury were more likely to need more time to obtain their previous performance level compared to horses without recurrent injury (HR = 0.54; 95% CI 0.29; 0.99).

Model diagnostics did not reveal violations of the model assumptions.

4 Discussion

High-power laser therapy was uneventfully applied in all horses with no skin burns, pain reactions or other adverse effects noticed. Application of high-power laser therapy therefore could be classified as a safe procedure in this population of horses. The applied treatment procedure in this study was associated with a significant improvement in lameness and ultrasonographic scores within 2 to 6 weeks after initiation of treatment.

Horses suffering from pathology involving DDFT, SL or SLB had a significantly higher lameness score at admission compared to those

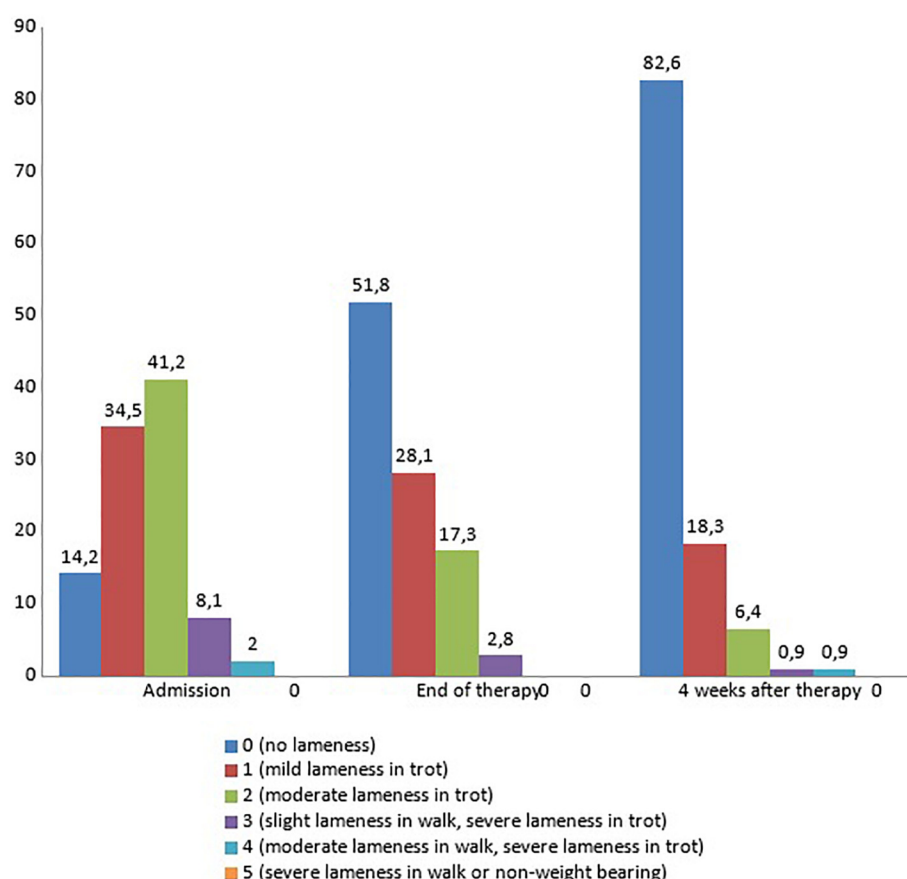


Fig 5 Short-term follow-up of lamenes scores.

suffering from SDFT tendinopathy. This is in agreement with literature, in which SDFT tendinopathy is reported to be less painful compared to affections of other tendinous or ligamentous structures (Dyson et al., 1995; Dyson, 2004; Ramzan et al., 2013; Schramme et al., 2010; Marneris and Dyson, 2014). Notwithstanding the wide variability in lameness score at admission, there was a statistically significant overall

improvement in both lameness and ultrasonographic scores the day after cessation of laser therapy (week 2) and 4 weeks later (week 6), across all types and stages of tendinopathy or desmopathy and both for horses diagnosed with a single disorder and for horses suffering from multiple causes of lameness. The lack of a control group precludes drawing of any conclusions about causal effects, but this finding can be

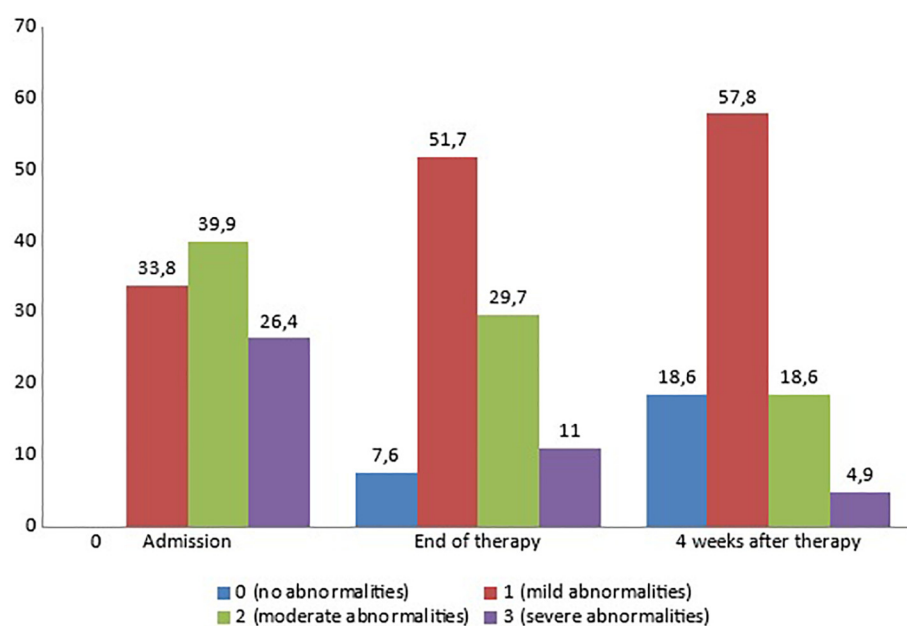


Fig 6 Short-term follow-up of ultrasound score.

Table 1

Long term follow-up.

	6 m		12 m		24 m	
No return	37/129	(28.7)	33/119	(27.7)	11/33	(33.3)
Lower level	20/129	(15.5)	12/119	(10.1)	4/33	(12.1)
Previous level	72/129	(55.8)	74/119	(62.2)	18/33	(54.5)
Re-injury	22/129	(16.8)	25/119	(21.0)	6/33	(18.2)

considered quite interesting, as the improvement manifests after a much shorter time interval than described in literature for other treatment modalities. Significant ultrasonographic improvement was seen after 5 (experimentally induced SDFT lesions) (Schramme et al., 2010) to 12 weeks (Geburek et al., 2016) of hand walking exercise and significant clinical improvement was seen 8 weeks after PRP treatment (naturally occurring SDFT lesions) in another study (Geburek et al., 2016). Based on these time periods it can be argued that the ultrasonographic appearance at 6 weeks is too early to have predictive value for the quality of repair. The lack of ultrasonographic follow-up after a longer time is indeed a weakness of the current study. However, the clinical follow-up period was much longer and it is generally accepted that neither lameness nor ultrasonographic appearance but re-injury rate represents the critical outcome parameter in studies on equine tendon healing.

Horses suffering from similar conditions and treated by other therapies than laser were not included, as this would require reviewing the medical background of several years back. Interpretations would be unreliable due to too much variation in veterinarians, diagnostic imaging, scoring method and rehabilitation protocol.

Application of an additional therapy did not seem beneficial in the current study, as horses receiving other treatment modalities in addition to laser therapy were more likely to have a worse lameness score at week 6. Whereas it can be conjectured that clinicians would be more inclined to use an additional therapy in case of a more severe lesion, this possibility is less probable considering there was no difference in lameness at admission. A more likely explanation is the inflammatory reaction that is known to often occur following injection with either PRP, ACP, fat-derived stem cells, bionic cells or hyaluronic acid. In the current study, intra- or perilesional injections were performed 2 days before the start of laser therapy and this might hence explain the higher degree of lameness seen at week 2 (not significant) and week 6 (significant) due to pain caused by an inflammatory reaction following injection. Laser therapy as a sole therapy results in a stronger amelioration of lameness compared to laser therapy combined with additional therapy. These results do suggest laser therapy as a sole therapy might be clinically favourable.

The median time for horses to return to exercise in the current study was 6 weeks and to return to previous performance level 6 months. The initial type of tendinopathy or desmopathy, stage of injury, presence of multiple orthopedic pathologies or use of an additional therapy did not affect time to return to previous performance level. This observation is in contrast with a number of earlier studies reporting a worse prognosis for chronic tendon injuries for which the low turn-over of tendon tissue is deemed to be responsible (Dyson et al., 1995; Ramzan et al., 2013; Schramme et al., 2010; Marneris and Dyson, 2014). Theoretically the outcome in the current study could possibly be explained by the biophysical properties of laser light. Both animal and human studies report that high-power laser therapy has important effects at tissue level, such as a mitochondrial stimulation with increased production of ATP, activation of the microcirculation and analgesic and anti-inflammatory effects (Guerra-Fda et al., 2013; Carrinho et al., 2006; Elwakil, 2007; Demir et al., 2013; Marcos et al., 2014; Casalechi et al., 2013; Larkin et al., 2012; Maegawa et al., 2000; Marcos et al., 2012; Laraia et al., 2012; Bjordal et al., 2006; Pires et al., 2011). However, this issue needs further research before any conclusions can be drawn.

The biophysical effects mentioned above could also be related to the rather low re-injury rate seen in the current study. Studies in rats and rabbits have demonstrated positive effects of high-power laser therapy on fiber alignment and tensile strength during tendon repair (Carrinho et al., 2006; Elwakil, 2007; Demir et al., 2013; Marcos et al., 2014; Casalechi et al., 2013). Fiber alignment is known to play a pivotal role in determining tensile strength in tendons, and hence in their resistance to strain and the associated risk for re-injury. The re-injury rates in the current study are lower than or within the lower ranges of those reported in other studies on treatment modalities for tendinopathy (Crowe et al., 2004). Re-injury rate of 135 horses (competing in varying disciplines) suffering from SDFT tendinopathy varied between 42.5 and 44.4 two years after the onset of full exercise following conservative treatment (controlled exercise with or without medical treatment with either hyaluronic acid or polysulphated glycosaminoglycans) (Kaneps, 2016; Schramme et al., 2010). Dyson and co-workers reported a re-injury rate of approximately 18 (in a study of 65 horses) after intralesional injection of beta aminopropionitrile (Dyson, 2004). PRP has been successfully applied in both equine SDFT tendinopathy and SL desmitis (Waselau et al., 2008; Castelijns et al., 2011), however large scale studies are lacking. Re-injury rate after stem cell therapy in SDFT tendinopathy was 27.4 in a study covering 113 (almost exclusively Hunt-) racehorses 2 years after the onset of full exercise (Godwin et al., 2012) and 18 in a study covering 168 racehorses (Smith, 2008). The fact that different types of tendinopathy or desmopathy (acute, sub-acute and chronic tendonitis and desmitis), with each a different etiology, pathogenesis and prognosis, as well as horses additionally treated with other therapies were included in the current study needs to be kept in mind and caution needs hence to be taken when comparing studies. Still, only a minority of horses received any additional therapy in the current study (33.3 %). These horses were not eliminated from the study to enable studying effects of laser therapy while combined with additional therapy.

If the horse had a history of a recurrent tendinopathy at the start of laser therapy, it took significantly longer to be back at the previous performance level. This is in line with earlier work showing that horses with a recurrent tendinopathy or desmitis have a worse long term prognosis (Dyson, 2004; Crowe et al., 2004) and therefore the rehabilitation period is expected to be longer.

We want to emphasize that the rehabilitation schemes that were used in previously published studies (Dyson, 2004; Kaneps, 2016) were considerably longer than the scheme used in our study (16 and 52 weeks versus 7 and 15 weeks in our study for introduction of respectively trot and normal atwork, including canter). The median time required to return to the previous exercise level was 6 months in our study, whereas canter is often not even included when applying more conservative rehabilitation schemes. The rehabilitation protocol designed for this study was based on clinical experience on previously laser treated horses. It is possible that the apparently faster start-up and build-up of rehabilitation in laser treated horses is an extra factor that supports healing, since in human medicine it has already been demonstrated that long-term inactivity impairs tendon healing (Mardh and Lund, 2016).

5 Main limitations

The main limitation of the current study was that there no control group. Further, some horses were lost to long-term follow-up. Other limitations include the variety in affected structures, including both tendinopathy and desmopathy cases, and the somewhat heterogeneous character of equestrian disciplines and levels the horses were competing in. Possible confounding factors were the application of additional treatments besides laser therapy in some horses and the disparity in rehabilitation protocols as these were adapted to match clinical progress of the individual horse. The clinical conditions of this type of study did not enable to avoid these limitations.

6 Conclusion

High-power laser therapy can be safely applied in horses. In the current study, a significant amelioration of lameness and ultrasound scores starting 2 weeks after initiation of high-power laser therapy was observed. Re-injury rate was within the lower ranges of previously published studies on several other treatment modalities. A rapid build-up of the rehabilitation program was possible. These findings are encouraging, however it should be acknowledged that the current study is a first explorative retrospective clinical study into the possible effects of this new device and suffers from several limitations that preclude drawing of firm conclusions. Nevertheless, outcome can be deemed encouraging enough to justify a program of prospective studies and controlled experimental studies that can help in obtaining more insight into the biophysical effects of high-power laser therapy on tendon and ligament healing.

Supplementary data to this article can be found online at <https://doi.org/10.1016/j.rvsc.2018.06.003>.

References

- Arqu  lles, D., Carmona, J.U., Climent, F., Munoz, E., Prades, M., 2008. Autologous platelet concentrates as a treatment for musculoskeletal lesions in five horses. *Vet. Rec.* 7, 208–211.
- Basford, J.R., Sheffield, C.G., Gieslak, K.R., 2008. Laser therapy: a randomized, controlled trial of the effects of low intensity Nd:YAG laser irradiation on lateral epicondylitis. *Arch. Phys. Med. Rehabil.* 81, 1504–1510.
- Bingol, U., Altan, L., Yurtkuran, M., 2005. Low-power laser treatment for shoulder pain. *Photomed. Laser Surg.* 23, 459–464.
- Bjor  dal, J.M., Lopes-Martins, R.A., Iversen, V.V., 2006. A randomised, placebo controlled trial of low level laser therapy for activated Achilles tendinitis with microdialysis measurement of peritendinous prostaglandin E2 concentrations. *Br. J. Sports Med.* 40, 76–80.
- Bosch, G., van Schie, H.A.T., de Groot, M.W., Cadby, J.A., van de Lest, C.H., Barneveld, A., van Weeren, P.R., 2010. Effects of platelet-rich plasma on the quality of repair of mechanically induced core lesions in equine superficial digital exor tendons: a placebo-controlled experimental study. *J. Orthop. Res.* 28, 211–217.
- Carrinho, P.M., Renno, A.C., Koeke, P., Salate, A.C., Parizotto, N.A., Vidal, B.C., 2006. Comparative study using 685-nm and 830-nm lasers in the tissue repair of tenotomized tendons in the mouse. *Photomed. Laser Surg.* 24, 754–758.
- Casalechi, H.L., Leal-Junior, E.C., Xavier, M., Silva Jr., J.A., de Carvalho, P., de Aimbire, T.F., Albertini, R., 2013. Low-level laser therapy in experimental model of collagenase-induced tendinitis in rats: effects in acute and chronic inflammatory phases. *Lasers Med. Sci.* 28, 989–995.
- Castelijns, G., Crawford, A., Schaffer, J., Ortolano, G., Beauregard, T., Smith, R., 2011. Evaluation of a filter-prepared platelet concentrate for the treatment of suspensory branch injuries. *Vet. Comp. Orthop. Traumatol.* 5, 363–366.
- Conforti, M., Fachinetti, G.P., 2013. High power laser therapy treatment compared to simple segmental physical rehabilitation in whiplash injuries (first and second grade of the Quebec task force classification) involving muscles and ligaments. *Muscles Ligaments Tendons J.* 3, 117–122.
- Crowe, O., Dyson, S., Writh, I., Schramme, M., Smit, R., 2004. Treatment of chronic or recurrent proximal suspensory desmitis using radial pressure wave therapy in the horse. *Equine Vet. J.* 36, 313–316.
- Demir, H., Menku, P., Kirnap, M., Calis, M., Ikizceli, I., 2013. Comparison of the effects of laser, ultrasound, and combined laser + ultrasound treatments in cartilage injury model. *Lasers Surg. Med.* 35, 84–89.
- Dyson, S.J., 2004. Management of superficial exor tendon tendinitis: a comparative study in 219 horses (1992–2000). *Equine Vet. J.* 36, 415–419.
- Dyson, S.J., Arthur, R.M., Palmer, S.E., Richardson, D., 1995. Suspensory ligament desmitis. *Vet. Clin. North. Am. Equine Pract.* 11, 177–215.
- Elwakil, T.F., 2007. An in-vivo experimental evaluation of He-Ne laser photostimulation in healing Achilles tendons. *Lasers Med. Sci.* 22, 53–59.
- Geburek, F., Gaus, M., van Schie, H.T., Rohn, K., Stadler, P.M., 2016. Effect of intralesional platelet-rich plasma (PRP) treatment on clinical and ultrasonographic parameters in equine naturally occurring superficial digital exor tendinopathies – a randomized prospective controlled clinical trial. *BMC Vet. Res.* 1, 191. <http://dx.doi.org/10.1186/s12917-016-0826-1>.
- Gillis, C.L., 2016. Rehabilitation of tendon and ligament injuries. *Proc. Am. Assoc. Equine Pract. Congr. Orlando US* 43 (3–7), 306–309 December 2016.
- Godwin, E.E., Young, N.J., Dudhia, J., Beamish, I.C., Smith, R.K., 2012. Implantation of bone marrow-derived mesenchymal stem cells demonstrates improved outcome in horses with overstrain injury of the superficial digital exor tendon. *Equine Vet. J.* 44, 25–32.
- Guerra Fda, R., Vieira, C.P., Almeida, M.S., Oliveira, L.P., de Aro, A.A., Pimentel, E.R., 2013. LLLT improves tendon healing through increase of MMP activity and collagen synthesis. *Lasers Med. Sci.* 28, 1281–1288.
- Kaneps, A.J., 2016. Therapies for equine soft tissue injuries. *Proc. Am. Assoc. Equine Pract. Cong. Orlando US* 62 (3–7), 241–244 December 2016.
- Lam, L.K., Cheing, G.L., 2007. Effects of 904-nm low-level laser therapy in the management of lateral epicondylitis: a randomized controlled trial. *Photomed. Laser Surg.* 25, 65–71.
- Laraia, E.M., Silva, I.S., Pereira, D.M., dos Reis, F.A., Albertini, R., de Almeida, P., Leal-Junior, E.C., de Tarso de Camillo de Carvalho, P., 2012. Effect of low-level laser therapy (660 nm) on acute inflammation induced by tenotomy of Achilles tendon in rats. *Photochem. Photobiol.* 88, 1546–1550.
- Larkin, K.A., Martin, J.S., Zeanah, E.H., True, J.M., Braith, R.W., Borsa, P.A., 2012. Limb blood flow after class 4 laser therapy. *J. Athl. Train.* 47, 178–183.
- Maegawa, Y., Itoh, T., Hosokawa, T., Yaegashi, K., Nishi, M., 2000. Effects of near-infrared low-level laser irradiation on microcirculation. *Lasers Surg. Med.* 27, 427–437.
- Marcos, R.L., Leal-Junior, E.C., Arnold, G., Magnenet, V., Rahouadj, R., Wang, X., Demeurie, F., Magdalou, J., de Carvalho, M.H., Lopes-Martins, R.A., 2012. Low-level laser therapy in collagenase-induced Achilles tendinitis in rats: analyses of biochemical and biomechanical aspects. *J. Orthop. Res.* 30, 1945–1951.
- Marcos, R.L., Arnold, G., Magnenet, V., Rahouadj, R., Magdalou, J., Lopes-Martins, R.A., 2014. Biomechanical and biochemical protective effect of low-level laser therapy in Achilles tendinitis. *J. Mech. Behav. Biomed. Mater.* 29, 272–285.
- Mardh, A., Lund, I., 2016. High power laser for treatment of Achilles tendinosis – a single blind randomized placebo controlled clinical study. *J. Lasers Med. Sci.* 7, 92–98.
- Marnieris, D., Dyson, S.J., 2014. Clinical features, diagnostic imaging findings and concurrent injuries in 71 sports horses with suspensory branch injuries. *Equine Vet. Educ.* 26, 312–321.
- Morimoto, Y., Saito, A., Tokuhashi, Y., 2013. Low level laser therapy for sports injuries. *Laser Ther.* 22, 17–20.
- Pires, D., Xavier, M., Araujo, T., Silva Junior, J.A., Aimbire, F., Albertini, R., 2011. Low-level laser therapy (LLLT; 780 nm) acts differently on mRNA expression of anti- and pro-inflammatory mediators in an experimental model of collagenase-induced tendinitis in rat. *Lasers Med. Sci.* 26, 85–94.
- Pryor, B.A., 2011. Advances in Laser Therapy for the treatment of work related injuries. In: Stout, C.E. (Ed.), *Current Perspectives in Clinical Treatment and Management on Workers' Compensation Cases*, 1st edn. Bentham Science Publishers Ltd, pp. 191–201.
- Ramzan, P., Palmer, L., Dallas, R., Shepherd, M., 2013. Subclinical ultrasonographic abnormalities of the suspensory ligament branch of the athletic horse: a survey of 60 thoroughbred racehorses. *Equine Vet. J.* 45, 159–163.
- Ryan, T., Smith, R.K.W., 2007. An investigation into the depth of penetration of low level laser therapy through the equine tendon in vivo. *Irish Vet. J.* 60, 295–299.
- Schramme, M., Hunter, S., Campbell, N., Blikslager, A., Smith, R., 2010. A surgical tendinitis model in horses: technique, clinical, ultrasonographic and histological characterization. *Vet. Comp. Orthop. Traumatol.* 23, 231–239.
- Smith, R.K., 2008. Mesenchymal stem cell therapy for equine tendinopathy. *Disabil. Rehabil.* 30, 1752–1758.
- Stashak, T.S., 2002. Examination for lameness. In: Stashak, T.S. (Ed.), *Adam's Lameness in Horses*, 5th edn. Lippincott Williams & Wilkins, Philadelphia, pp. 113–183.
- Stergioulas, A., Stergioula, M., Aarskog, R., Lopes-Martins, R.A., Bjor  dal, J.M., 2008. Effects of low-level laser therapy and eccentric exercises in the treatment of recreational athletes with chronic Achilles tendinopathy. *Am. J. Sports Med.* 36, 881–887.
- Waselau, M., Sutter, W.W., Genovese, R.L., Bertone, A.L., 2008. Intralesional injection of platelet-rich plasma followed by controlled exercise of midbody suspensory ligament desmitis in Standardbred racehorses. *J. Am. Vet. Med. Assoc.* 10, 1515–1520.
- Wiegerinck, J.I., Kerkhoffs, G.M., van Sterkenburg, M.N., Siersevelt, I.N., van Dijk, C.N., 2012. Treatment of insertional Achilles tendinopathy: a systematic review. *Knee Surg. Sports Traumatol. Arthrosc.* D01. <http://dx.doi.org/10.1007/s00167-012-2219-8>.